

Orthobiological Augmentation of Consecutive Rotator Cuff Repair Failure and Deltoid Dehiscence

CPT Shawn Gee, MC USA*; CPT John Dunn, MC USA†; MAJ Brian Waterman, MC USA†; MAJ Michael Todd, MC USA†

ABSTRACT We present a case of postsurgical deltoid insufficiency occurring after augmented revision of a failed prior rotator cuff repair. Revision deltoid repair with deltoid imbrication and orthobiological augmentation was dually performed, resulting in successful deltoid and rotator cuff healing and improved clinical outcomes.

INTRODUCTION

Deltoid dehiscence or insufficiency is a rare complication following rotator cuff repair (RCR) that can contribute to poor clinical outcomes.¹ Postoperative deltoid disruptions typically occurs in the following scenarios: failure of repaired deltoid muscle and fascia after an open RCR, excessive deltoid detachment from the lateral acromion in mini-open RCR, and/or overly aggressive anterior acromioplasty with inappropriate anterior deltoid release, typically during arthroscopic RCR.² During open RCR, deltoid dehiscence is not uncommon, occurring in approximately 8% of patients and generally within 3 months of surgery (range, 1–5 months).¹ When disrupted, patients may complain of increased or persistent shoulder pain, diminished range of motion, and/or decreased strength with forward flexion and abduction.

Current recommendations for treatment of symptomatic failed RCR with deltoid insufficiency include open direct primary repair or deltoidplasty.³ Although less optimal, conservative treatment followed by delayed primary repair has also been described in the literature.⁴ Poor clinical outcomes associated with revision RCR include prior lateral acromionectomy, involvement of the middle deltoid, a massive rotator cuff tear with weakness in external rotation, and a residual postoperative defect larger than 2 cm.³

CASE REPORT

We present the case of a 39-year-old male Army service member with a symptomatic, small full-thickness rotator cuff tear and pain for over 10 years that failed to respond of conservative treatment. The service member was otherwise healthy and was taking no supplements. At the time of surgery, a 1.5-cm supraspinatus tear was repaired arthroscopically using a

transosseous-equivalent, double row technique, and the patient was immobilized for 4 weeks followed by gradual mobilization. At 8 months postoperatively, he continued to complain of anterolateral shoulder pain with corresponding physical examination findings consistent with biceps tendon pathology to include positive Speed's and Yergason's tests. Of note, the patient also had intact axillary nerve function throughout his clinical course. The patient elected to precede with subpectoral biceps tenodesis, whereupon a large, recurrent, retracted supraspinatus and infraspinatus tear were discovered intraoperatively. Although interval releases restored some cuff mobility, only partial repair through mini-open fashion was possible and orthobiological augmentation with dermal allograft scaffold (GraftJacket, Wright Medical, Branchburg, New Jersey) was utilized. Deltoid repair was performed through side-to-side closure and bone tunnels in the lateral acromion, and a conservative postoperative regimen was undertaken.

Despite continued therapy, the patient continued to complain of pain and difficulty with forward flexion and abduction 5 months after revision, and physical examination revealed a palpable defect in the vicinity of the deltoid repair. Subsequent magnetic resonance imaging confirmed deltoid dehiscence with maintenance of rotator cuff integrity, and surgical repair was offered (Fig. 1). Revision bone tunnel repair through the lateral acromion using nonabsorbable suture with deltoid imbrication sown in-line with concomitant single layer allograft dermal augmentation was performed (Fig. 2). After 8 weeks of immobilization, physical therapy was resumed with gentle passive and active assist range of motion. At 3 months postoperatively, the patient reported dramatic improvement of pain symptoms, and he was able to achieve 150 degrees of forward flexion, 120 degrees of abduction, and 60 degrees of external rotation. Surveillance magnetic resonance imaging revealed early incorporation of allograft scaffold without evidence of tear recurrence either in the deltoid or rotator cuff, and the patient reported a continually improving clinical course. At 7 months postoperatively, the patient was able to achieve 150 degrees of forward flexion, 108 degrees of abduction, and 70 degrees of external rotation (Fig. 3). He had 4+/5 strength on supraspinatus and infraspinatus testing, although 4/5 shoulder was detected on forward flexion. The patient

*Department of Orthopaedic Surgery, Tripler Army Medical Center, 459 Patterson Road, Honolulu, HI 96819.

†Department of Orthopaedic Surgery, William Beaumont Army Medical Center, 5005 North Piedras, El Paso, TX 79920.

The opinions or assertions contained herein are the private views of the authors and are not to be construed as official or reflecting the views of the Department of Defense or the U.S. Government. The authors are employees of the U.S. Government.

doi: 10.7205/MILMED-D-14-00251

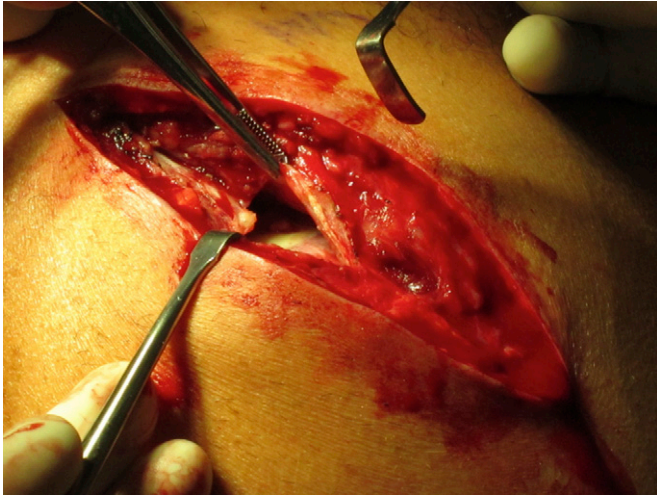


FIGURE 1. Intraoperative photo of deltoid dehiscence. The rotator cuff repair is intact deep to the deltoid, which is being held with the tissue forceps.

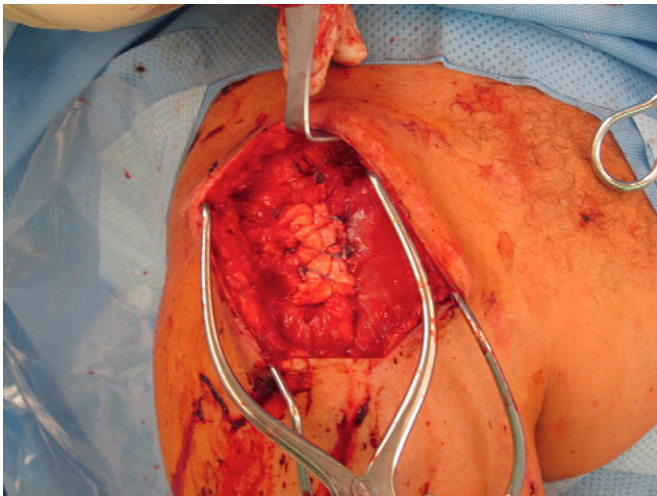


FIGURE 2. Deltoid imbrication and concomitant allograft biologic augmentation.

complained of occasional, sharp 2/10 pain on repetitive overhead shoulder range of motion, although he was able to perform 73 push-ups on his military physical fitness test. He ultimately elected for permanent upper extremity limitations under a physical profile because of persistent cervical neck complaints and has continued on active duty military service.

DISCUSSION

In this case report, we describe the successful consecutive treatment of secondary rotator cuff and deltoid failure with revision repair and concomitant orthobiologic augmentation. With this repair, our patient achieved excellent range of motion, pain relief, and was able to continue on active duty military service. Although not uncommon in isolation, the combination of RCR failure and deltoid dehiscence represents a rare clinical entity.

The etiology of the initial rotator cuff tear progression after repair and deltoid dehiscence is unclear in our case. Many cases of deltoid dehiscence include iatrogenic injury to vascular or neurologic structures during both open and arthroscopic shoulder surgery, although the cause is often unknown.⁵ Blazar et al⁶ reported a series of 3 patients who had spontaneous detachment of the deltoid with concomitant massive rotator cuff tears.

Successful RCR depends on proper diagnosis and treatment based on tear configuration, tendon integrity, fatty infiltration, patient age, and medical comorbidities.² Failure of RCRs results from diagnostic errors, technical error, inadequate biologic remodeling, and/or traumatic failure.⁷ In the current case, the rotator cuff tissue failure may be attributable to poor tissue quality and patient noncompliance. In cases of failed RCR, tissue is often massively retracted and scarred, requiring extensive tendon mobilization to achieve anatomic repair, although this is sometimes not possible. In similar circumstances, poor tissue quality or partial repair can benefit from orthobiological augmentation, particularly using biologic scaffolds. Orthobiological augmentation ensures footprint coverage in areas of poor tissue quality or incomplete

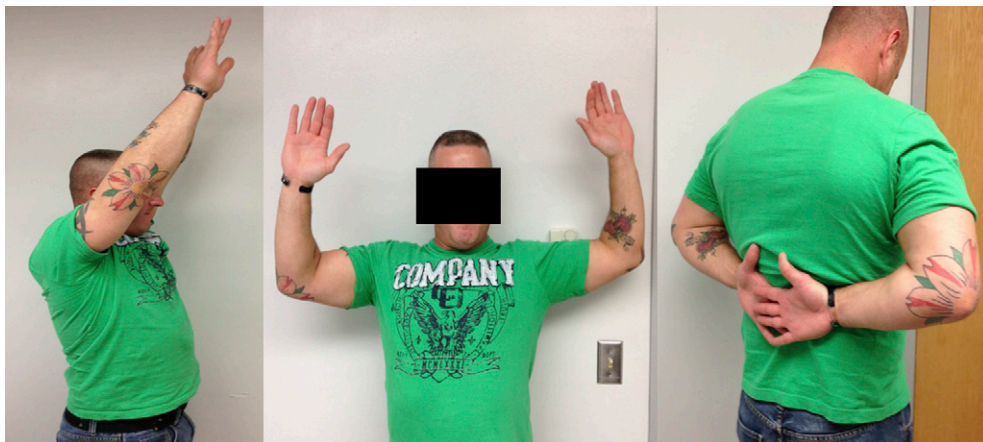

FIGURE 3. Clinical range of motion evaluation postoperatively.

tendon mobility and recreates appropriate length-tendon relationship and forces coupling of tissue which can help restore range of motion and ultimately tissue health. In a series of 17 patients undergoing scaffold augmentation for massive rotator cuff tears, Burkhead et al⁵ demonstrated pain improvement in 64% of patients and functional status improvement in 70% of patients at a mean follow-up of 1.2 years. Currently, the American Academy of Orthopaedic Surgeons cannot recommend for or against the use of soft tissue allografts and other xenografts to treat patient with rotator cuff tear, mainly because of the lack of high-quality studies. However, the American Academy of Orthopaedic Surgeons does recommend against the use of non-cross-linked, porcine small intestine submucosal xenograft patch to treat patients with rotator cuff tears.⁸ In two studies (level II and III), there were less favorable outcomes in those that used the porcine graft, as opposed to those that had a primary repair.^{9,10} In our case study, the rotator cuff was repaired using orthobiological augmentation with dermal allograft scaffold with reasonable short-term clinical results.

Although infrequent, deltoid dehiscence can have significant repercussions on shoulder function and patient-reported outcomes, even with operative management. Without prompt recognition and surgical treatment, patients with conservative treatment may experience up to 86% unsatisfactory results with activities of daily living.³ For deltoid failure after open RCR, Gumina et al¹ recommended the use of a "U-type" suture with thread thicker than number two nonabsorbable suture to achieve a biomechanically stable direct repair. When accompanied by rotationplasty, patients with deltoid repairs may still report suboptimal outcomes. In a series of 24 patients, Sher et al³ demonstrated that only 4% and 29% of patients reporting excellent and good results, respectively, after rotationplasty and direct repair, whereas 67% of patients reported unsatisfactory outcomes. In this study, however, satisfactory outcomes required that multiple, stringent subjective, and objective criteria, including minimal discomfort, fully functional use as assessed by the ASES score, subjective patient satisfaction with postoperative outcome, active elevation to 135 degrees, rotational range of motion of at least 90% of the contralateral side, and full strength.³ Currently, there are no known prior reports of orthobiological augmentation for cases of deltoid dehiscence.

Scaffold materials vary widely and are derived from numerous sources, including those of skin, mucosal, or tendinous origin. Ultimately, these materials are suited to support cellular processes from the tissue in which they are harvested. As an example, collagen fibers within a ligament or tendon are highly aligned along the load-bearing axis. Biologic scaffolds are biodegradable substrate that provide structural support and promote reconstructive remodeling including angiogenesis, cell proliferation, cell migration, and cell differentiation.²

In the short-term, scaffolds typically lose strength because of in vivo degradation. Degradation of small intestine submucosa scaffold material occurs rapidly, losing 50% at 1 month and complete degradation by 3 months.¹¹ During this time, infiltrating cells proliferate and organize reproducing mechanical behavior of that site. Recent in vitro studies, have demonstrated improved mechanical properties when physiological mechanical loading was allowed during the remodeling process.^{12,13} As a result, partial load bearing postoperatively may improve the strength of the graft.

In summary, deltoid dehiscence is a rare complication after prior open RCR occurring in up to 8% of patients, resulting in poor patient outcomes.⁴ In these instances, orthobiological augmentation can serve as a useful adjunct in the treatment of both postoperative rotator cuff and deltoid insufficiency of the shoulder with favorable patient outcomes.

REFERENCES

- Gumina S, Di Giorgio G, Perugia D, Postacchini F: Deltoid detachment consequent to open surgical repair of massive rotator cuff tears. *Int Orthop* 2008; 32(1): 81–4.
- George MS, Khazzam M: Current concepts review: revision rotator cuff repair. *J Shoulder Elbow Surg* 2012; 21(4): 431–40.
- Sher JS, Iannotti JP, Warner JJ, Groff Y, Williams GR: Surgical treatment of postoperative deltoid origin disruption. *Clin Orthop Relat Res* 1997; (343): 93–8.
- Akgun U, Kocaoglu B, Karahan M: Full recovery of muscle function after delayed primary repair of deltoid muscle detachment. *Int J Shoulder Surg* 2008; 2(4): 79–82.
- Burkhead WZ, Schiffert SC, Krishnan SG: Use of graft jacket as an augmentation for massive rotator cuff tears. *Semin Arthroplasty* 2006; 18(1): 11–8.
- Blazar PE, Williams GR, Iannotti JP: Spontaneous detachment of the deltoid muscle origin. *J Shoulder Elbow Surg* 1998; 7: 289–92.
- Badylak SF, Freytes DO, Gilbert TW: Extracellular matrix as a biological scaffold material: structure and function. *Acta Biomater* 2009; 5(1): 1–13.
- American Academy of Orthopaedic Surgeons: Optimizing the Management of Rotator Cuff Problems. Guideline and Evidence Report. Rosemount, IL, AAOS, 2010.
- Iannotti JP, Codsí MJ, Kwon YW, Derwin K, Ciccone J, Brems JJ: Porcine small intestine submucosa augmentation of surgical repair of chronic two-tendon rotator cuff tears. A randomized, controlled trial. *J Bone Joint Surg Am* 2006; 88(6): 1238–44.
- Walton JR, Bowman NK, Khatib Y, Linklater J, Murrell GA: Restore orthobiologic implant: not recommended for augmentation of rotator cuff repairs. *J Bone Joint Surg Am* 2007; 89(4): 786–91.
- Gilbert TW, Stewart-Akers AM, Simmons-Byrd A, Badylak SF: Degradation and remodeling of small intestinal submucosa in canine Achilles tendon repair. *J Bone Joint Surg Am* 2007; 89(3): 621–30.
- Liang R, Woo SL, Takakura Y, Moon DK, Jia F, Abramowitch SD: Long-term effects of porcine small intestine submucosa on the healing of medial collateral ligament: a functional tissue engineering study. *J Orthop Res* 2006; 24(4): 811–9.
- Musahl VAS, Gilbert TW, Tsuda E, et al: The use of porcine small intestinal submucosa to enhance the healing of the medial collateral ligament: a functional tissue engineering study in rabbits. *J Orthop Res* 2004; 22(1): 214–20.